

# **Audiological Findings and Rehabilitation in Children with Inner Ear Malformations**

**GONCA SENNAROĞLU PhD  
LEVENT SENNAROĞLU MD**

**Department of Otolaryngology  
Hacettepe University**

# Outline

---

To present the audiological findings and rehabilitative outcomes of CI in children with cochlear malformation

Hearing loss is common in children

There are many potential causes, both congenital  
and acquired

“Cochlear malformations have been reported  
to occur in approximately 20% of children with  
congenital sensorineural hearing loss

Sennaroglu, 2002 , Jackler, 1987 and Jansen 1969

# CONGENITAL SNHL

- Membranous malformations 80 %
  - Pathology at cellular level
  - Radiology normal
- Bony malformations 20 %
  - Pathology involves bony labyrinth
  - Radiology demonstrates the pathology

COCHLEAR IMPLANTS INTERNATIONAL, Vol. 11 No. 1, March, 2010, 4-41

## **Cochlear Implantation in Inner Ear Malformations — A Review Article**

LEVENT SENNAROGLU

*Department of Otolaryngology, Hacettepe University Medical Faculty,  
Ankara, Turkey*

# Hacettepe Results

- First implantation : 1997
- 1997- June 2011 : 1270 cases
- 132 cases with malformations (10 %)

# Classification

▫ Michel deformity	6%
▫ Cochlear aplasia	5%
▫ Common cavity	8%
▫ Cochlear hypoplasia	12%
▫ Incomplete Partition	41%
▪ IP-I (Cystic cochleovestibular malformation)	20%
▪ IP-II (Mondini deformity)	19%
▪ IP-III (X-linked Deafness)	2%
▪ LVAS	15%

# Hacettepe experience with malformations

## CI (107)

■ Hypoplasia	8
■ Common Cavity	6
■ IP-I	29
■ IP-II	35
■ IP-III	2
■ LVAS	21
■ Vestibular dilatation	4
■ Narrow IAC	1
■ Defective cochlear base	1

## ABI (25)

■ Michel Deformity	5
■ Cochlear Aplasia	6
■ Cochlear aperture aplasia	2
■ Common cavity (CNØ)	2
■ Cochlear hypoplasia (CNØ)	9
■ IP-I (CNØ )	1

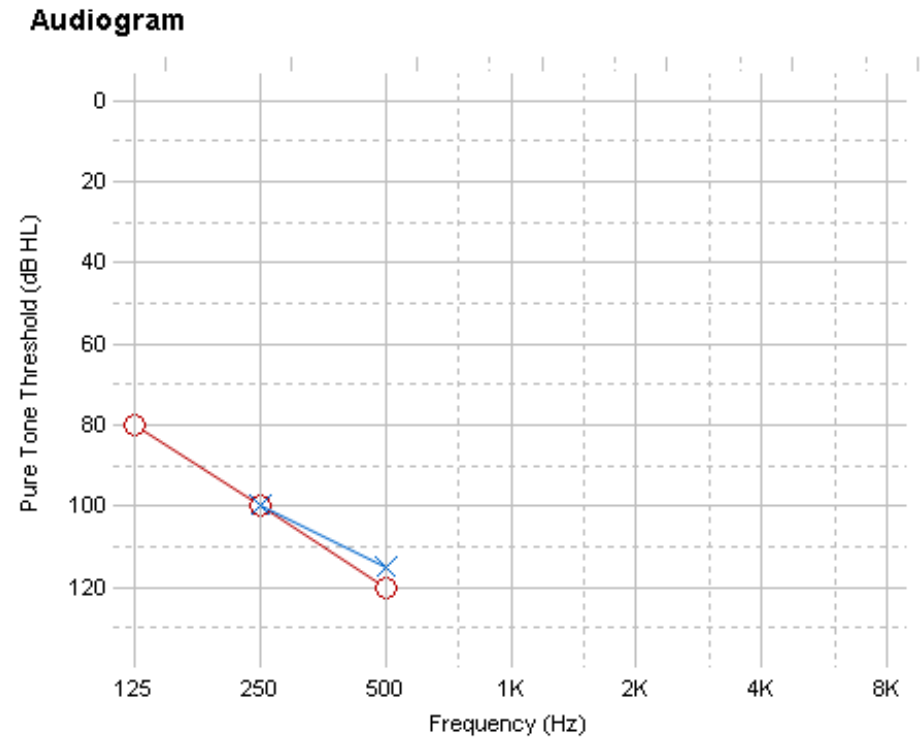


# Hearing Aid Users

- Hearing aids can be used until severe to profound hearing level in
  - Incomp part I (rarely)
  - Incomp part II
  - Incomp part III
  - LVAS
  - Hypoplasia

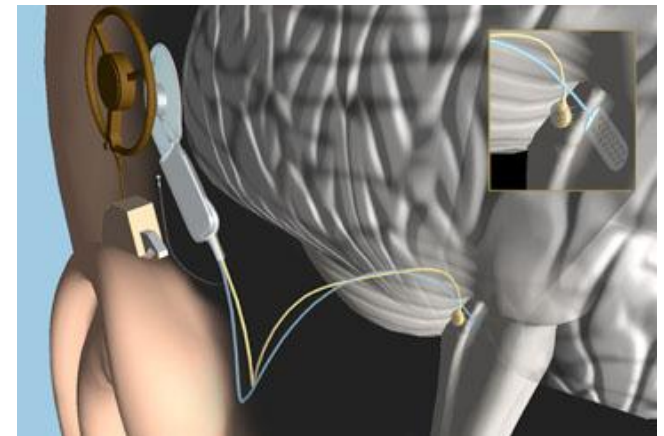
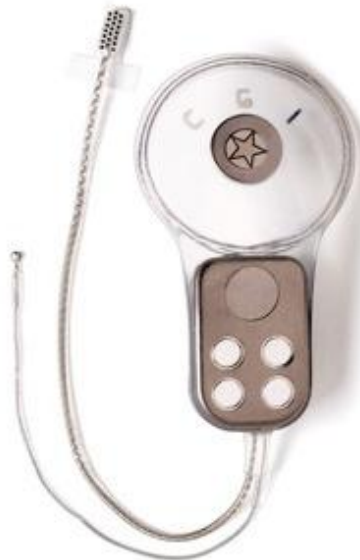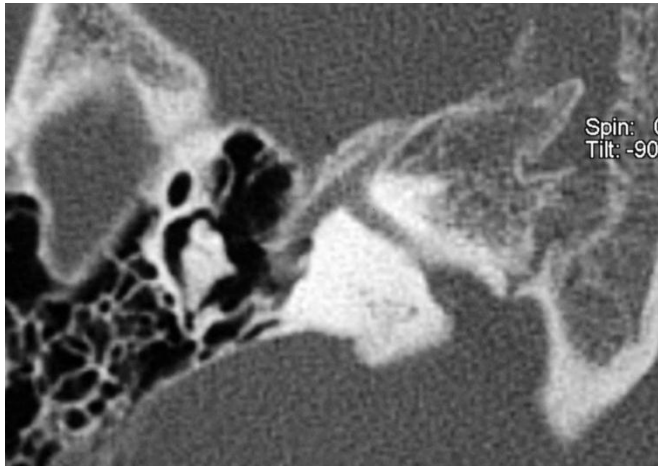
# Labyrinthine Aplasia (Michel)

- 6% of the cochlear malformations
- The most severe malformation
- Either there is no response or profound hearing loss at 125, 250 and 500 Hz at maximum audimetric limits



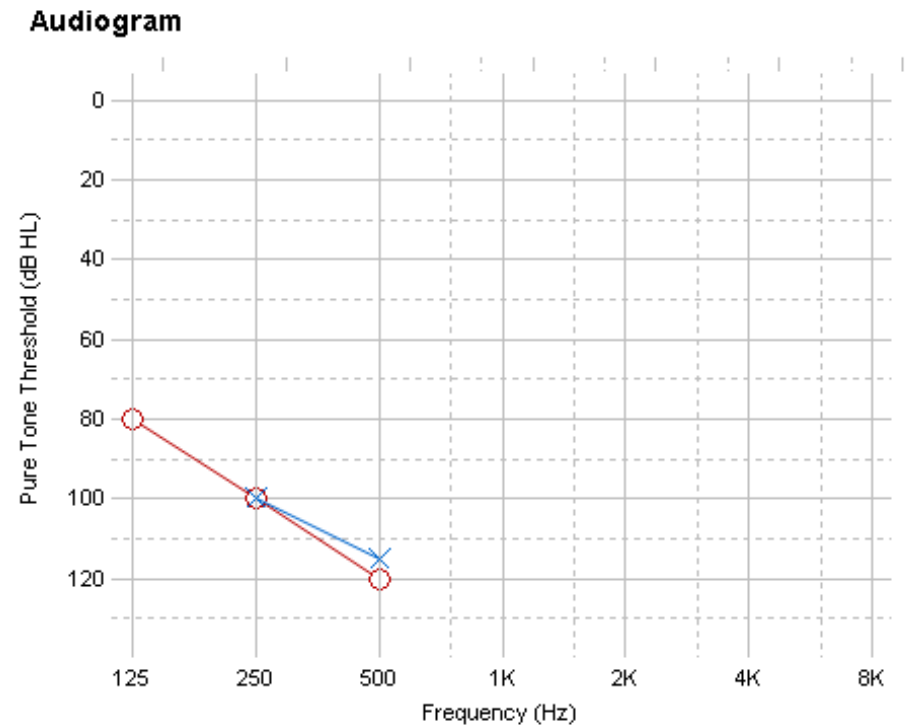
# Labyrinthine Aplasia (Michel)

- CI contraindicated
- Auditory Brainstem Implant (ABI) can be done



# Cochlear Aplasia

- 5% of the cochlear malformations
- Either there is no response or profound hearing loss at 125, 250 and 500 Hz at maximum audimetric limits



# Cochlear Aplasia

---

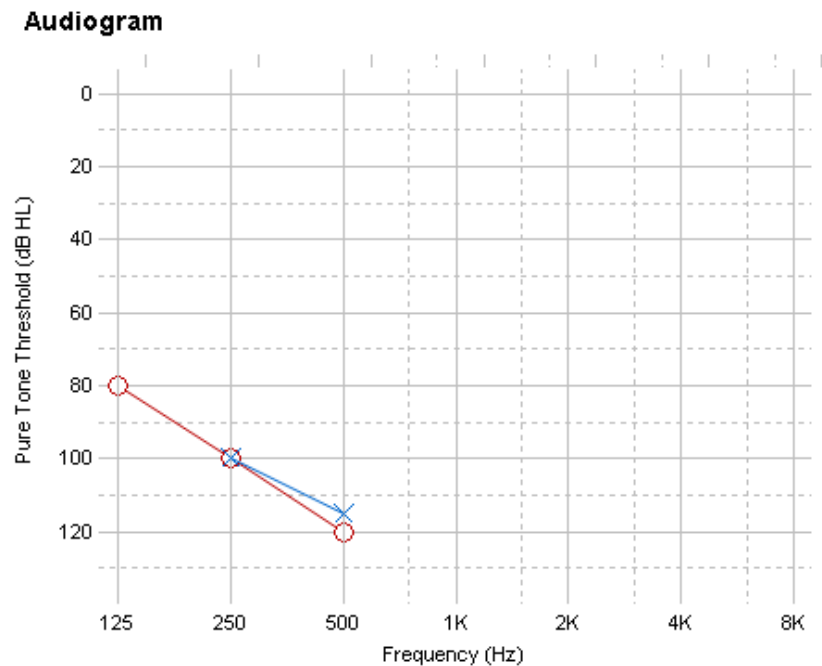
- CI contraindicated
- ABI is the only option

# Common Cavity

- 8% of cochlear malformations
- Round or ovoid structure representing cochlea and vestibule
- Cochlear nerve may be absent

# Common Cavity

- They only had thresholds on low frequency with maximum audimetric limits



- This 5 year old male patient had profound SNHL
- After CI surgery he developed near normal speech and language.
- It is possible to develop good audiological outcome in some patients
- Majority have poor outcome with CI and HA.



# Postop follow-up

- Nystagmus on initial hook-up
- Present on all electrodes
- C-level adjusted
- Continuing adaptation
- No nystagmus after 3 months

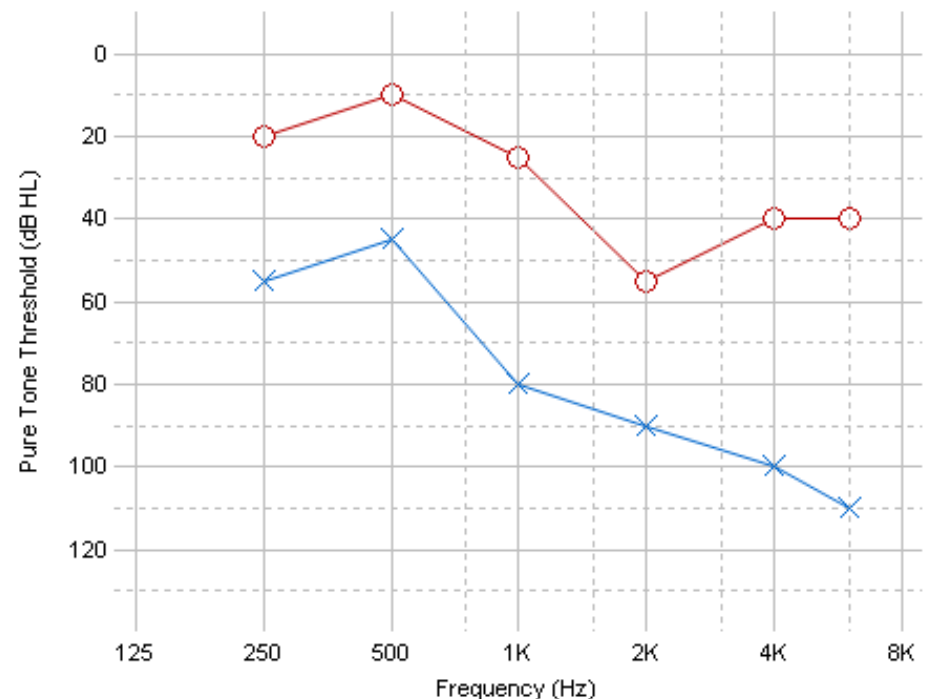
# Cochlear Hypoplasia

- 12% of cochlear malformations
- Cochlear aperture may be aplastic
- Cochlear nerve may be absent
- Three different forms are present

# Cochlear Hypoplasia

- Some patients had mild SNHL who make use of hearing aids with normal language development

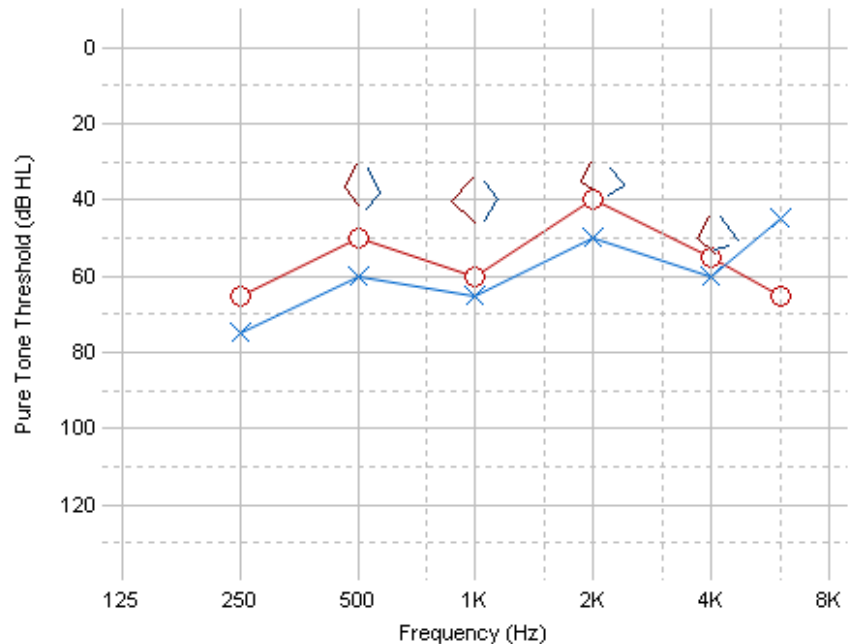
Audiogram



# Cochlear Hypoplasia

- This is another example of moderate SNHL who is rehabilitated with hearing aids
- They may show air-bone gaps without middle ear pathology

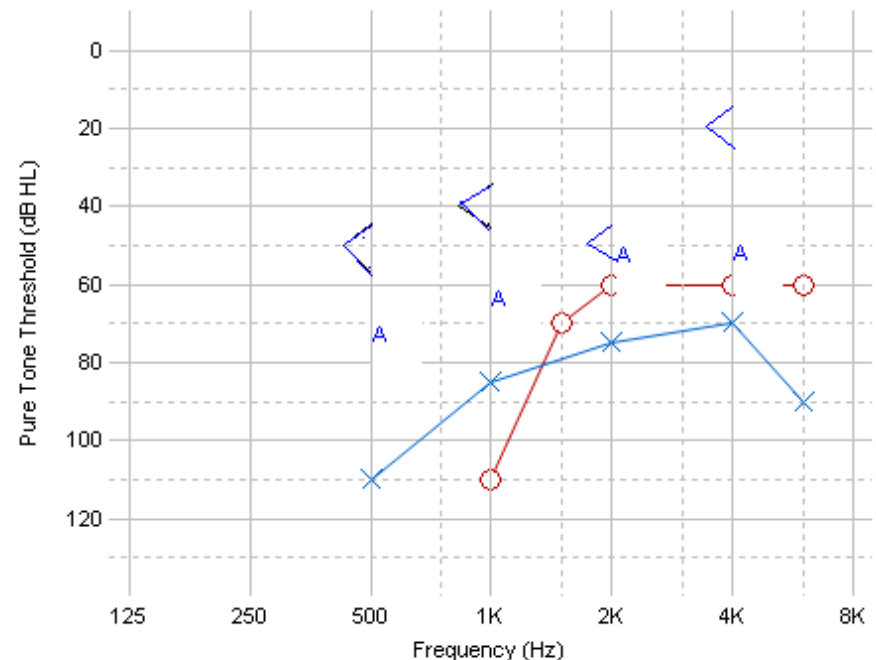
Audiogram



# Cochlear Hypoplasia

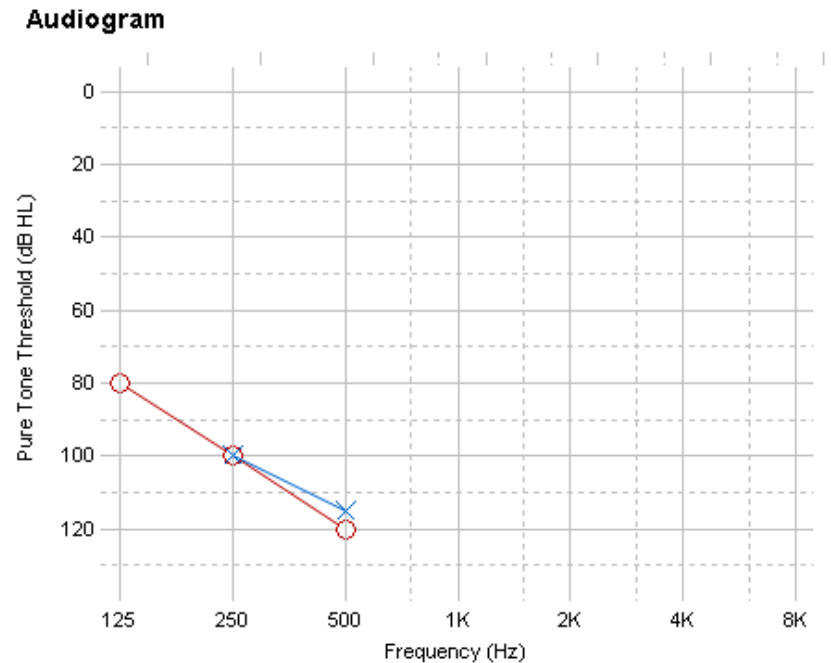
- Sometimes cochlear apex is missing and they have only the base of the cochlea
- They have better hearing level at high frequencies than the low frequencies

Audiogram



# Cochlear Hypoplasia

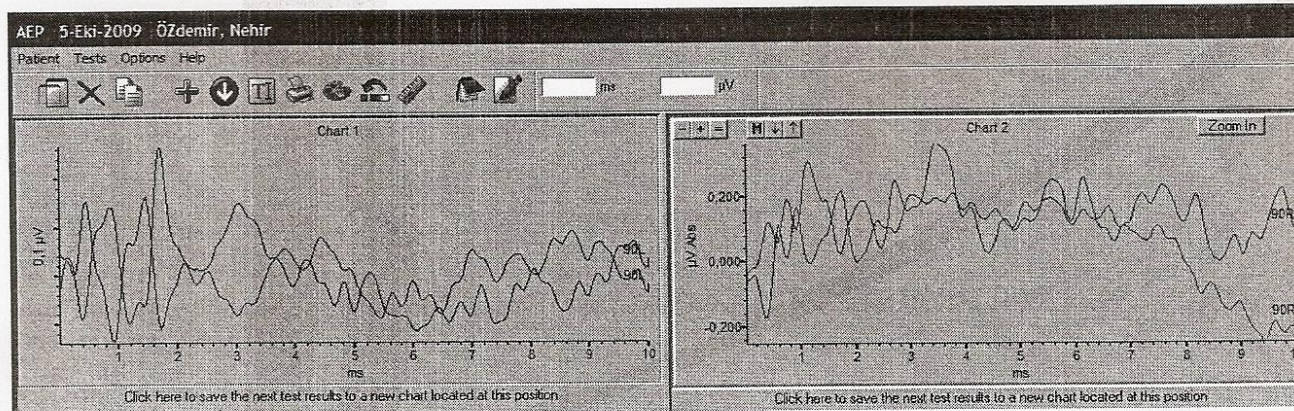
- Profound hearing loss at 125, 250 and 500 Hz at maximum audimetric limits
- They are candidates for CI or ABI



# Cochlear Hypoplasia

- If they have absent cochlear aperture or absent cochlear nerve CI is contraindicated, ABI should be done.
- Patients with hypoplastic nerve is very difficult to decide between CI and ABI

# NÖ



90 dBnHL, 11/s rate, -/+ polarity, click stimulus was used  
None of the wave forms (I,III,V) were observed  
Waveforms that invert when a click polarity is changed  
(rarefaction  $\longleftrightarrow$  condensation ) indicate the presence of a CM,  
implying hair cell function.

# AN ?



- MRI was reported to have no nerve on either side

# Auditory perception skills

- Ling's 6 sound detection/identification:

Unaided: a

IT MAIS: 2/40

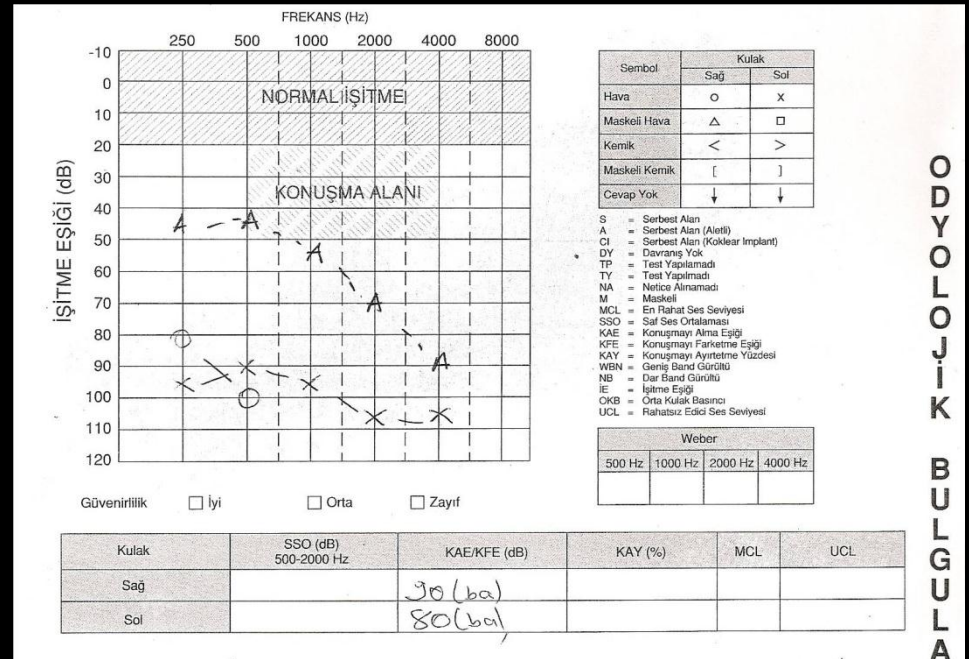
Aided (9 mon): a,u,m,sh

IT MAIS:21/40


- ESP (Pattern perception) Low version: 6/12

# NÖ

- With insert earphones there was clear and consistent response on the left side.
- She underwent left CI




# Incomplete Partition Types



Normal Cochlea



Type I



Type II



Type III

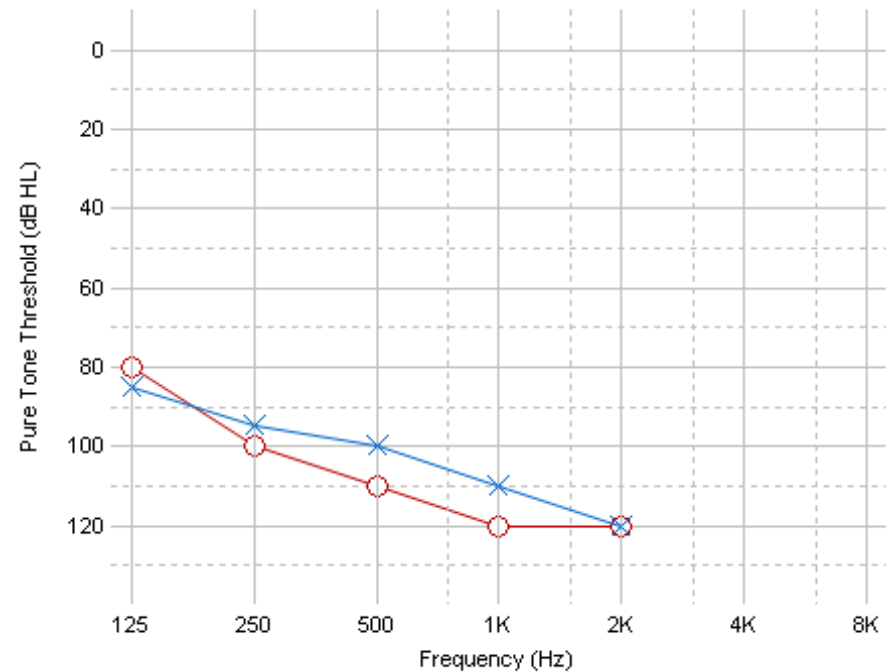
# IP-I (Cystic Cochleovestibular Malformation)

- 20% of cochlear malformations
- Cystic cochlea, dilated vestibule
- CI can be done if CN is present

# IP-I (Cystic cochleovestibular malformation)

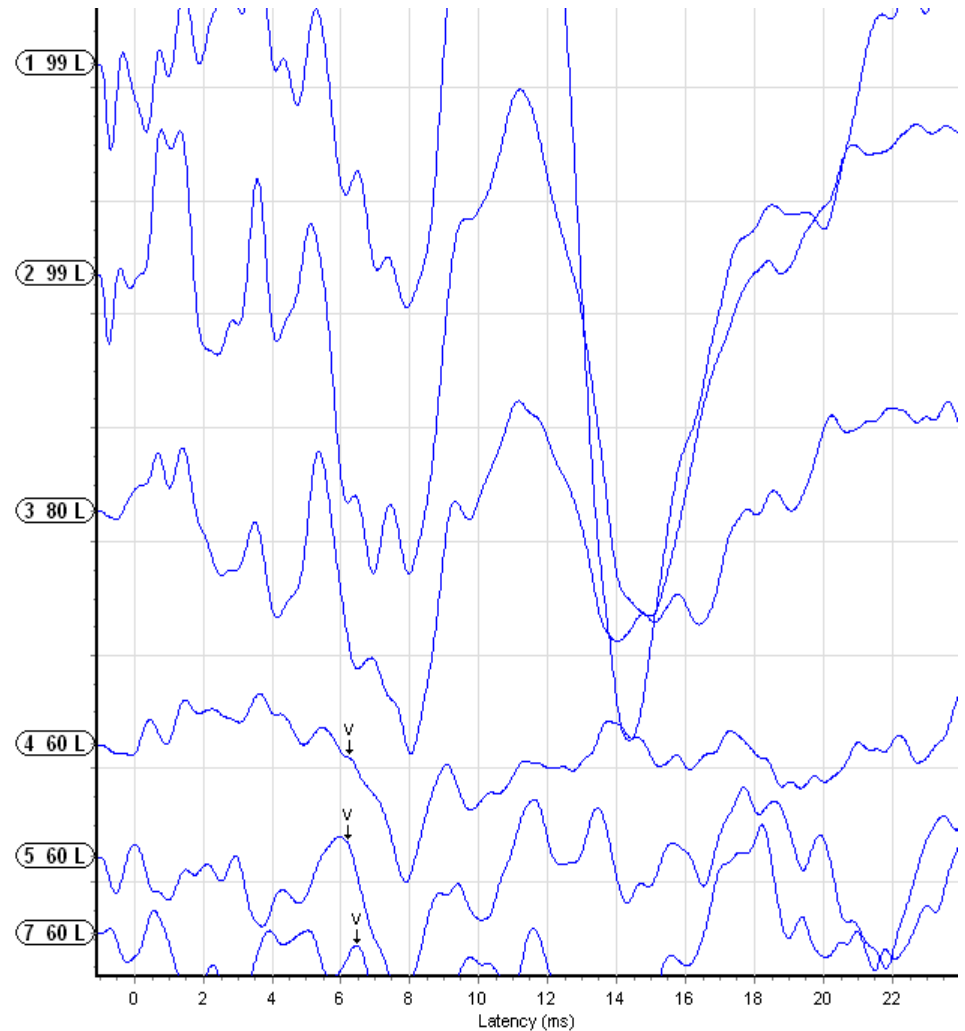
- Majority of IP-I patients had severe to profound SNHL
- Majority of this group can be rehabilitated with CI

Audiogram



# IP-I

- Three patients presented with moderate hearing loss unilaterally, where the contralateral ear had profound loss
- This is very rare
- They were rehabilitated with hearing aids



# IP-1

- After cochlear implantation they show slower progress in the first two years
- Sometimes initial response to sound can be seen after 6-12 months

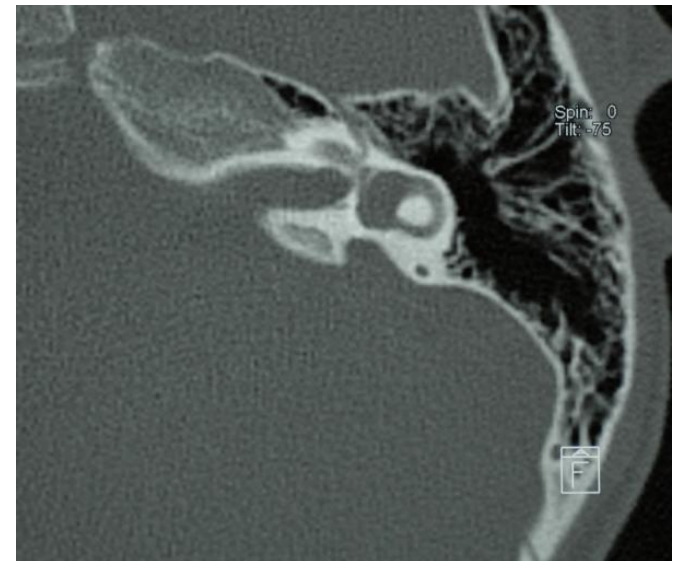
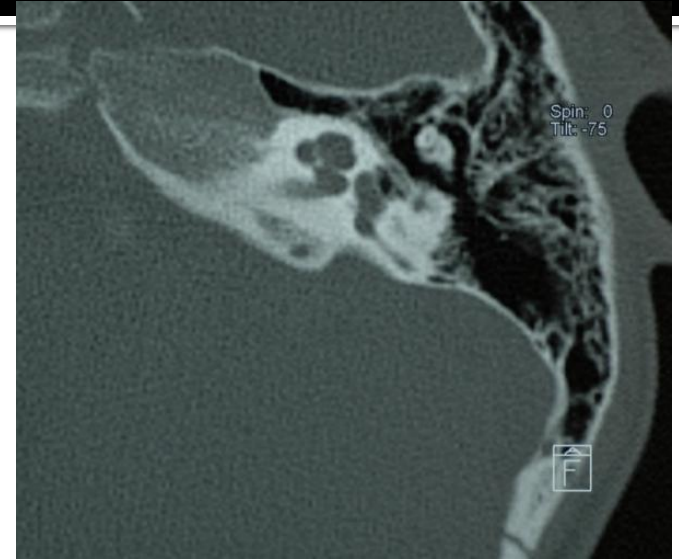

# IP-II (Mondini Deformity)

- 19% of cochlear malformations
- Described by Carlo Mondini
- Triad:
  - Cystic cochlear apex
  - Minimally dilated vestibule
  - Large vestibular aqueduct

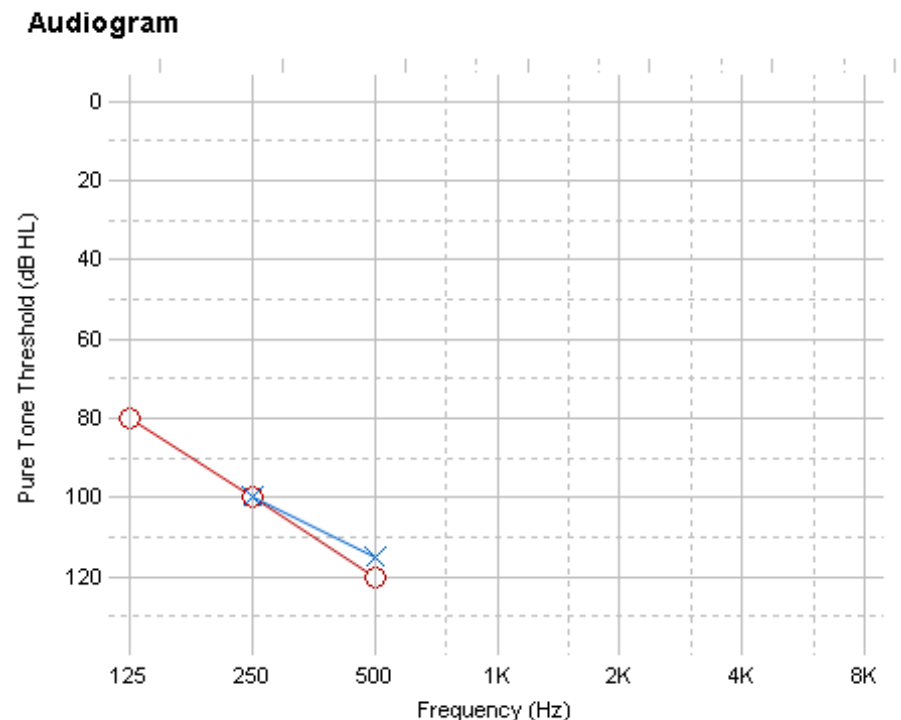
# IP-II (Mondini Deformity)

- They do not have a characteristic hearing configuration
- Hearing level in these patients changes throughout the lifetime



# IP-II (Mondini Deformity)

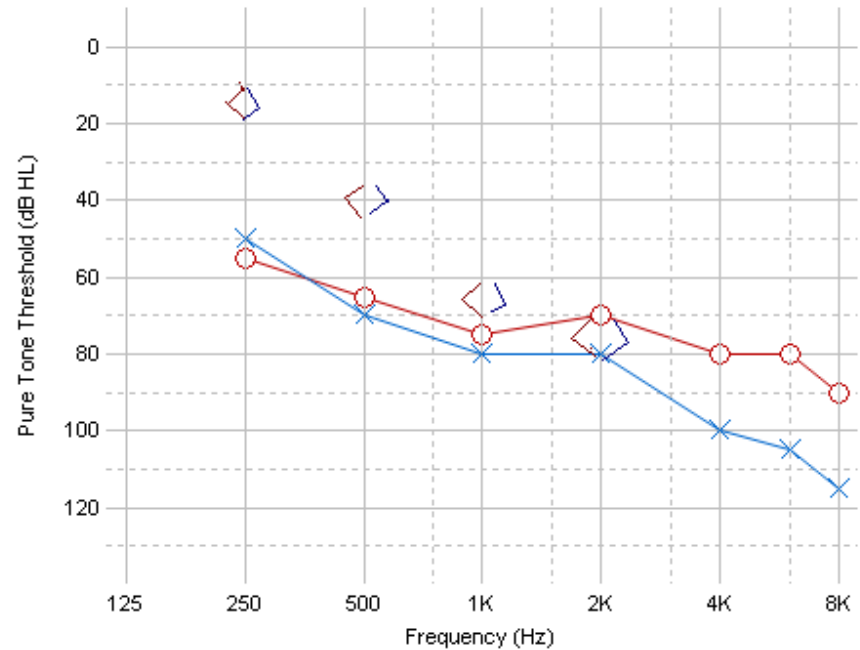
- Some patients have profound SNHL during birth or infancy
- They undergo CI surgery very early in their life



# IP - II

- Majority of IP-II patients have better hearing levels and they can develop near normal speech with hearing aids

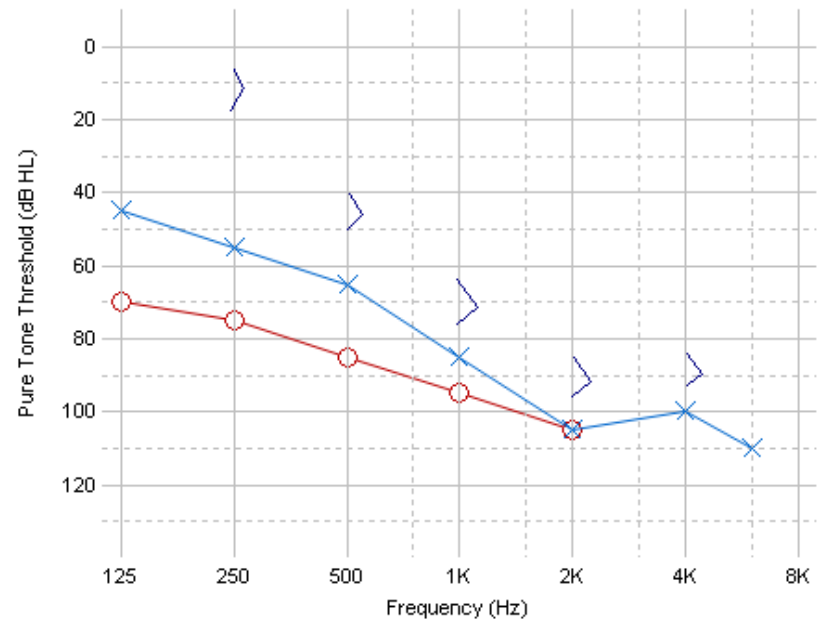
Audiogram



# IP - II

- They may also show an air-bone gap at low frequencies without any middle ear pathology
- Most probably due to large vestibular aqueduct acting as a third window

Audiogram



# IP-II

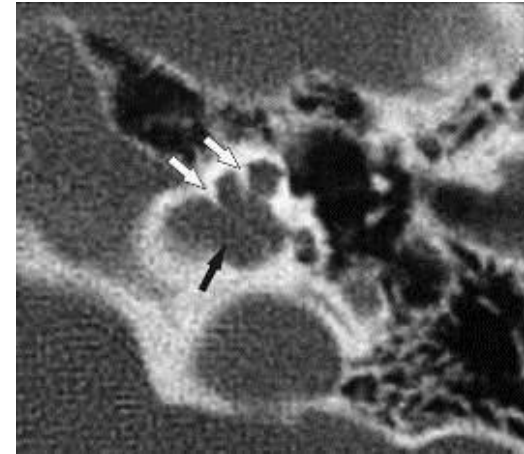
- With cochlear implantation they demonstrate improvement similar to patients with normal cochlea

# IP-III (X-linked deafness)

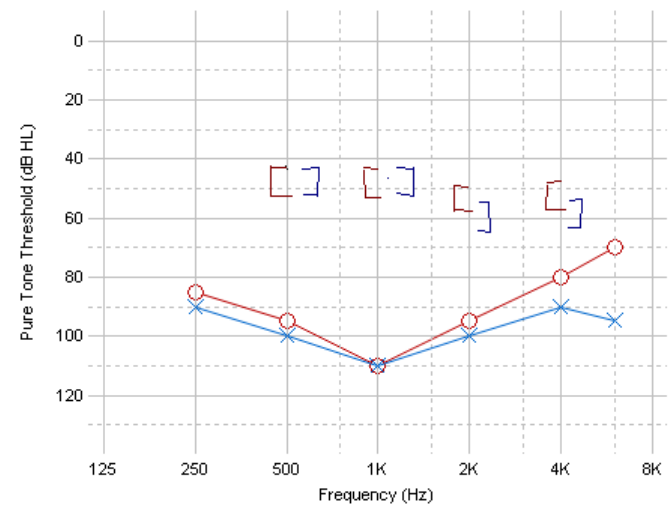
- 2% of cochlear malformations
- Described as X-linked deafness
- Gusher is present
- May be misdiagnosed as mixed type hearing loss

# Incomplete Partition III

- They may apply with mixed type hearing loss
- Snik et al. reported that if the degree of hearing loss was not too much, stapedius reflex could be obtained in this group of patients. They explained the air bone gap with the third window phenomenon. Because of the air-bone gap, stapedectomy was attempted in these patients in the past which resulted in gusher.
- When compared with the air-bone gap of IP-II patients, the gap is usually larger than the one in latter group involving high frequencies as well as low frequencies



Audiogram



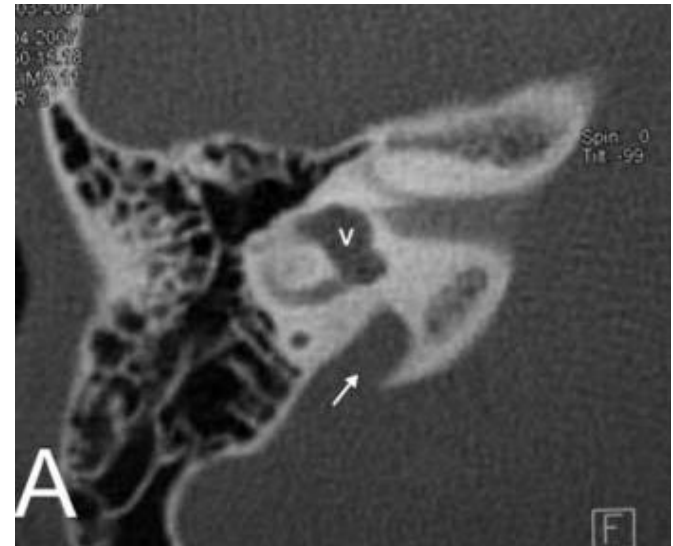

# IP-III

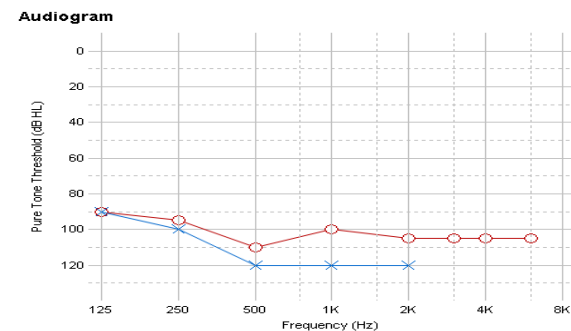
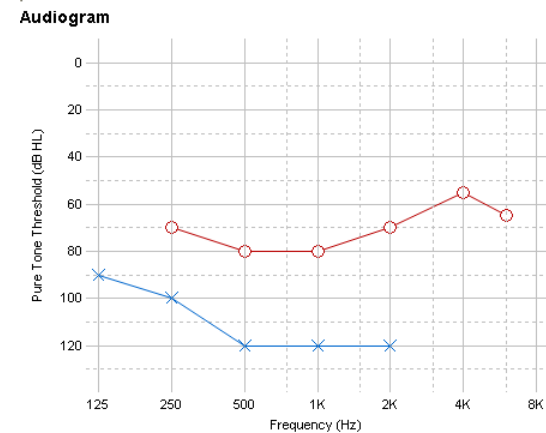
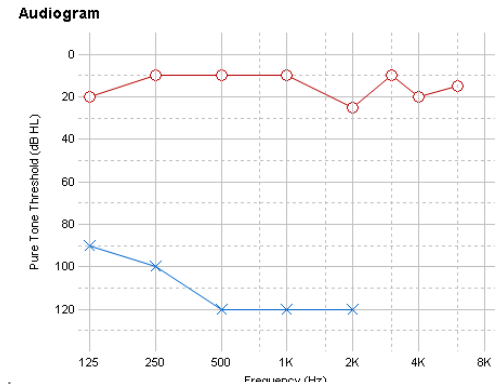
- With cochlear implantation they may demonstrate side effects such as facial nerve stimulation

# Large Vestibular Aqueduct Syndrome

- 15% of cochleovestibular malformations
- Midpoint between the posterior labyrinth and operculum  $> 1.5$  mm



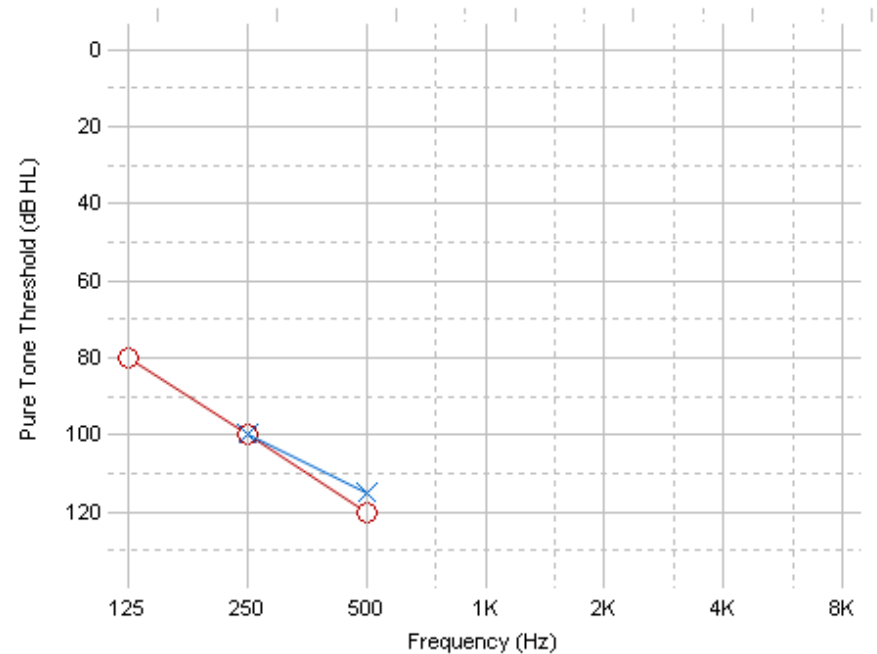
- Hearing is usually not stable and usually shows progressive loss over time
- The hearing level also shows fluctuations and sometimes sudden SNHL



# LVAS

- The other common form of presentation is profound SNHL

Audiogram



# Air-Bone Gap

- Air-bone gap in LVA is not due to disease in the middle ear.
- LVA introduces a third mobile window into the inner ear, which can produce an air-bone gap.

# Third Mobile Window

- It cause shunting the air-conducted sound away from the cochlea, thus elevating air conduction thresholds
- It increases the difference in impedance between the scala vestibuli and scala tympani side of the cochlear partition during bone conduction testing, thus improving thresholds for bone conducted sound.

# Results of Malformed Group

- Common cavity deformity
- IP-I (Incomplete partition I)
- IP-II(Incomplete partition II)
- Large Vestibular Aquaduct Synd.

**\* All had full insertion**

# Matching variables

- Age at implantation
- Duration of deafness
- Preoperative speech perception
- All pairs were enrolled in the same auditory training program
- $N_{\text{Control group}} : 16$
- $N_{\text{malformed}} : 16$

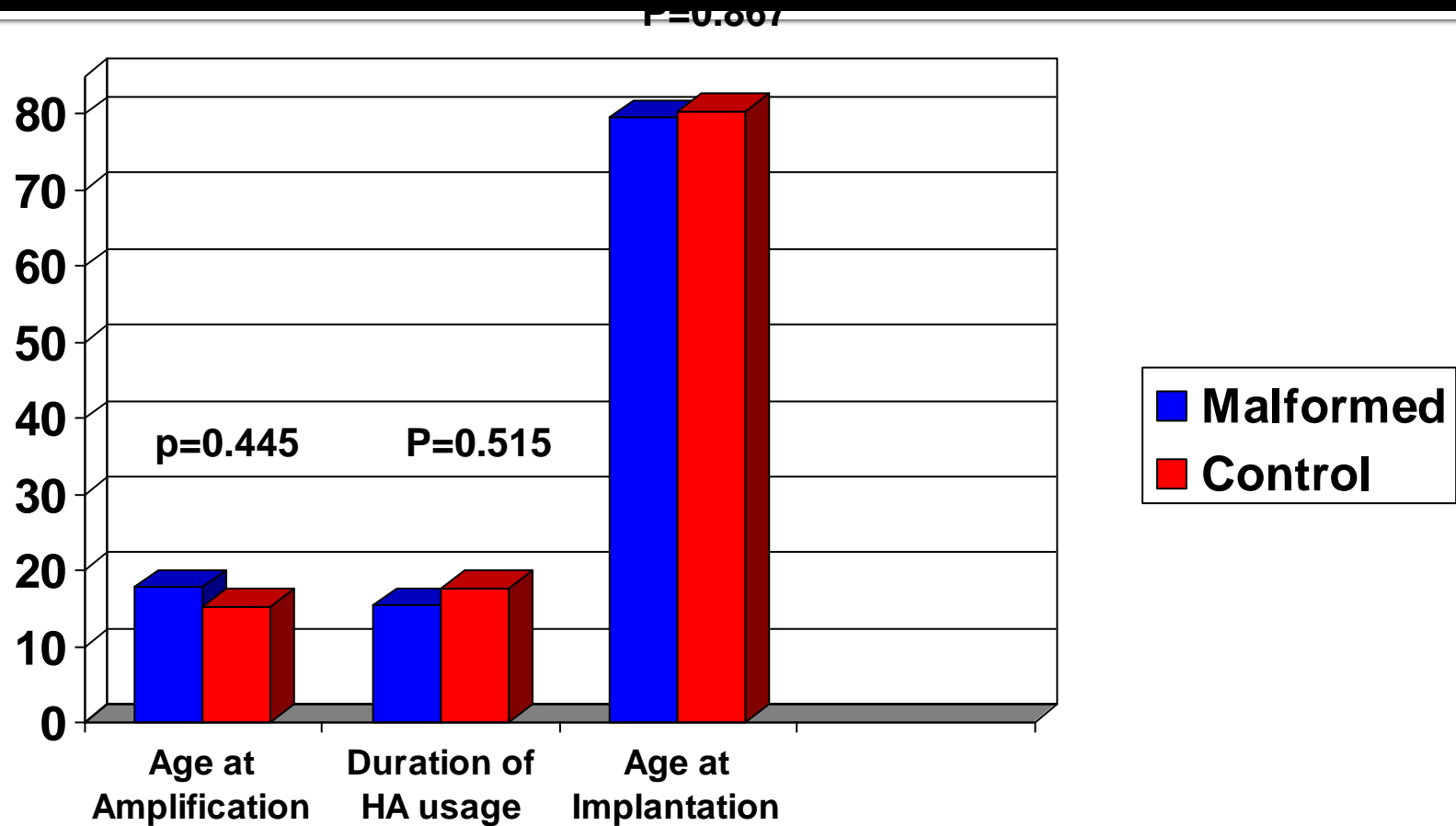


# Performance Data

---

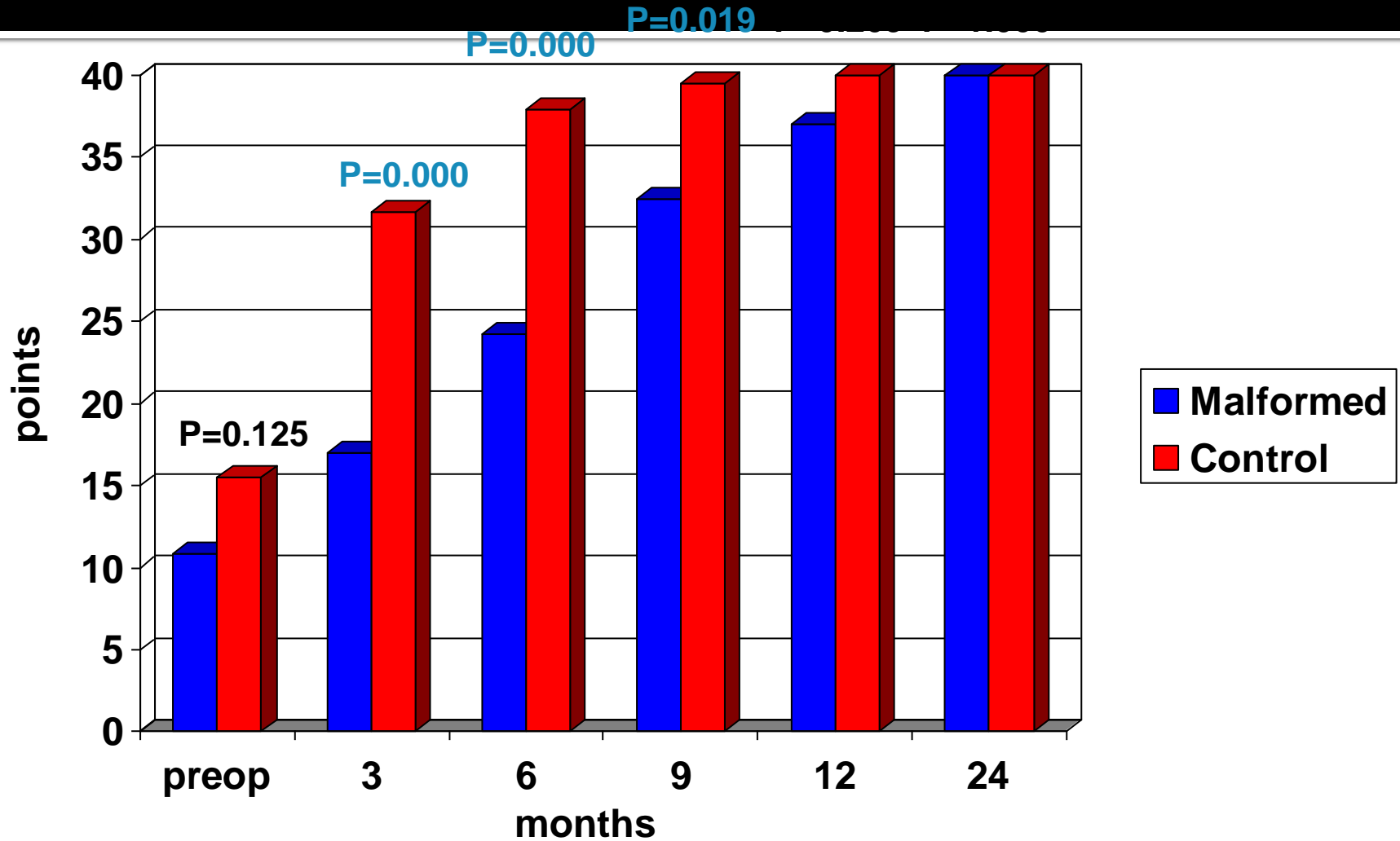
- **Early Speech Perception (ESP)**
- **MAIS or IT MAIS**
- **Mr. Potato Head**

# Results



**$P > 0.05$  for considered matching variables**

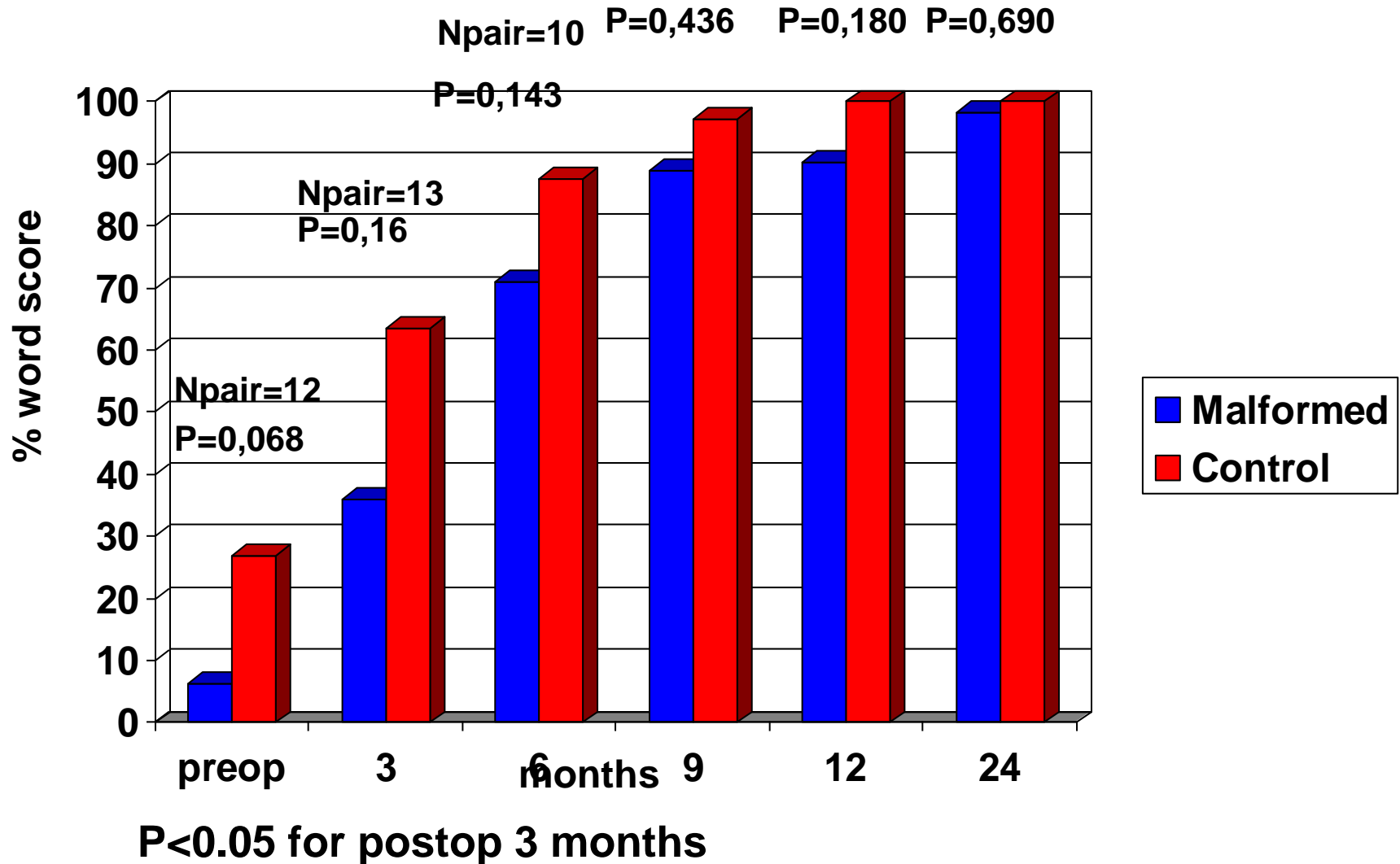
# MAIS or IT-MAIS



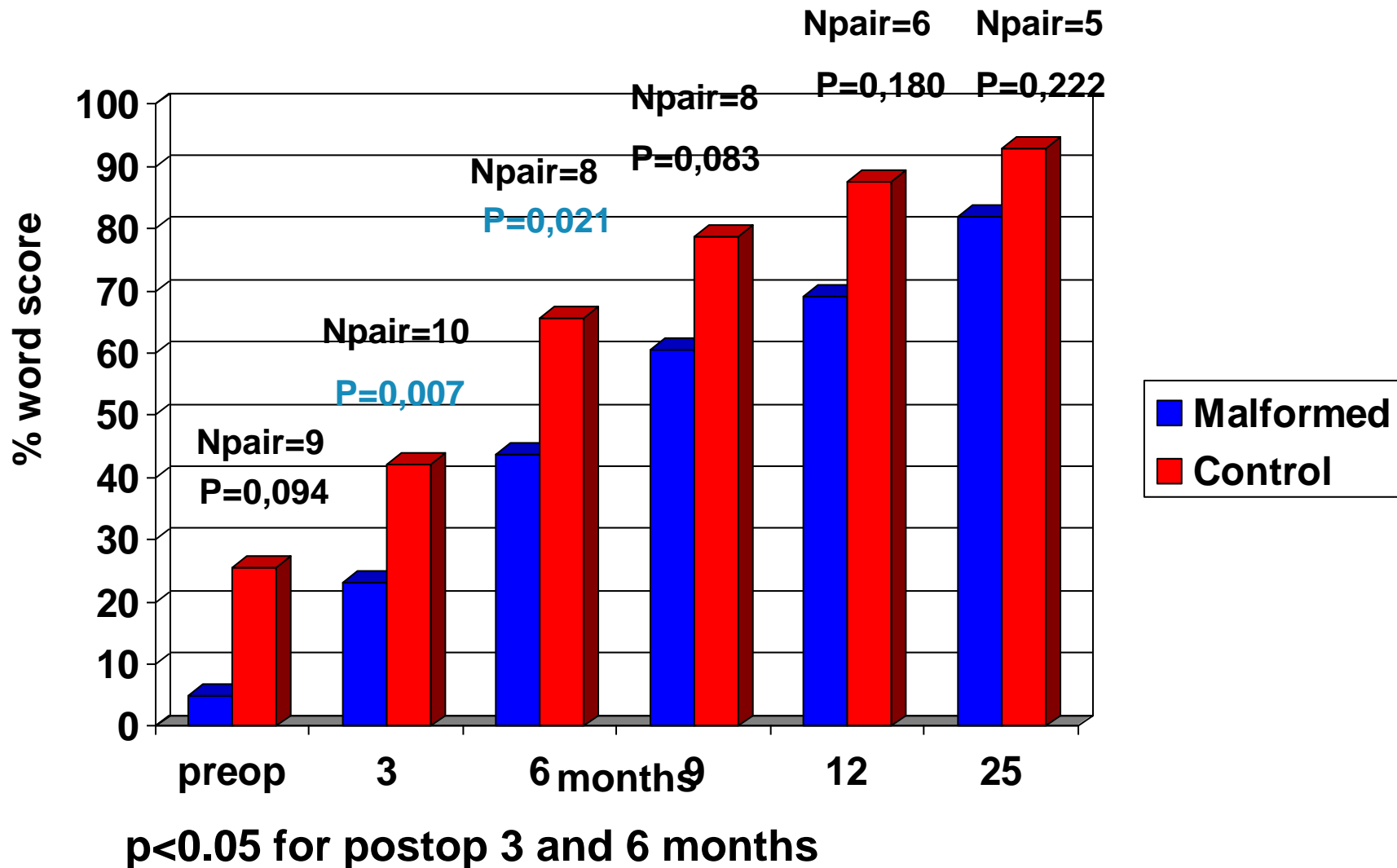
**P<0.05 for postop 3, 6, 9 months**

# ESP

(Age at imp:13-120)



# Mr. Potato Head



# Conclusion

- Children with malformed cochleae demonstrate significant improvements in their speech recognition skills with comparison with their preoperative performance with hearing aids
- The rate of postimplantation improvement is slower than that of children with normal cochleae

# VERY IMPORTANT!

---

During the preoperative counseling the child's parents must be informed that the results are uncertain depending on the severity of the malformation

Effective treatment strategies are available,  
and the earlier the detection and therefore  
intervention, the better is the outcome



